



## TUBERCULOSIS OF SPINE: CLINICAL AND RADIOLOGICAL CORRELATION – A SYSTEMATIC REVIEW AND META-ANALYSIS

Souvik Panja<sup>1</sup>, Sudipta Biswas<sup>2</sup>, Parthasarathi Mondal<sup>3\*</sup>

<sup>1</sup>Assistant Professor, Department of General Medicine, Santiniketan Medical College and Hospital, Bolpur, West Bengal, India.

<sup>2</sup>Assistant Professor, Department of Orthopaedics, Santiniketan Medical College and Hospital, Bolpur, West Bengal, India.

<sup>3</sup>Assistant Professor, Department of General Medicine, Santiniketan Medical College and Hospital, Bolpur, West Bengal, India.

**Corresponding Author:** Parthasarathi Mondal

Assistant Professor, Department of General Medicine, Santiniketan Medical College and Hospital, Bolpur, West Bengal, India.

**Email:** <sup>3\*</sup>[pmondal322@gmail.com](mailto:pmondal322@gmail.com)

### ABSTRACT

**Background:** Spinal tuberculosis (STB), also known as Pott's disease, is the most common form of skeletal tuberculosis and remains a significant cause of spinal deformity, neurological disability, and morbidity worldwide. Early diagnosis is often challenging because clinical manifestations are nonspecific and may overlap with other spinal disorders. Radiological evaluation, particularly magnetic resonance imaging (MRI), plays a crucial role in the detection and assessment of disease severity. Understanding the relationship between clinical presentation and radiological findings is essential for timely diagnosis and appropriate management.

**Objective:** To systematically evaluate the clinical manifestations, radiological characteristics, and their correlation in patients with spinal tuberculosis through a comprehensive systematic review and meta-analysis.

**Methods:** A systematic review and meta-analysis were conducted according to PRISMA guidelines. Electronic databases including PubMed, Scopus, Embase, Web of Science, Cochrane Library, and Google Scholar were searched for studies published between January 2000 and December 2025. Observational studies reporting clinical and radiological findings in patients with spinal tuberculosis were included. Data extraction and quality assessment were performed independently by two reviewers. Random-effects meta-analysis was used to calculate pooled prevalence estimates and odds ratios (ORs) with 95% confidence intervals (CIs).

**Results:** Twenty-three studies comprising 5,482 patients were included in the final analysis. The pooled mean age was 41.8 years, and 59.1% of patients were male. Back pain was the most common clinical manifestation, occurring in 89.6% (95% CI: 84.2–93.3%) of patients, followed by constitutional symptoms in 63.4% (95% CI: 56.8–69.5%). Neurological deficits were present in 34.8% (95% CI: 28.7–41.4%) of patients. Thoracic spine involvement was the most frequent anatomical location (47.5%), followed by thoracolumbar (29.2%) and lumbar regions (18.4%). Vertebral body destruction (72.1%) and paravertebral abscess formation (67.3%) were the most common radiological findings. MRI demonstrated pooled sensitivity and specificity of 95.8% and 92.7%, respectively, for the diagnosis of spinal tuberculosis. Meta-analysis revealed a significant association between MRI evidence of spinal cord compression and neurological deficits (OR = 5.84, 95% CI: 3.72–9.16;  $p < 0.001$ ). Kyphotic deformity and extensive vertebral destruction were also significantly associated with neurological impairment.

**Conclusion:** Chronic back pain, thoracic vertebral involvement, vertebral destruction, and paravertebral abscess formation represent the predominant clinical and radiological features of spinal tuberculosis. MRI remains the gold-standard imaging modality owing to its high diagnostic accuracy and ability to detect neural compression and soft tissue involvement. Significant correlations between radiological severity and neurological deficits emphasize the importance of early clinico-radiological evaluation for preventing irreversible neurological complications and optimizing patient outcomes.

**Keywords:** Spinal Tuberculosis, Pott's Disease, Magnetic Resonance Imaging, Clinical-Radiological Correlation, Neurological Deficit, Vertebral Destruction, Systematic Review, Meta-Analysis.



[www.ajmrhs.com](http://www.ajmrhs.com)  
eISSN: 2583-7761

Date of Received: 20-04-2026  
Date Acceptance: 10-05-2026  
Date of Publication: 15-06-2026

### INTRODUCTION

Tuberculosis (TB) remains one of the most significant infectious diseases worldwide and continues to pose a major public health challenge despite advances in diagnosis and treatment. According to the World Health Organization

(WHO), approximately 10.8 million people developed tuberculosis globally in 2023, with low- and middle-income countries accounting for the majority of cases. Although pulmonary tuberculosis constitutes the predominant form of the disease, extrapulmonary tuberculosis contributes substantially to morbidity, disability, and healthcare burden, particularly in endemic regions [1].

Musculoskeletal tuberculosis accounts for approximately 10–20% of extrapulmonary tuberculosis cases, and spinal tuberculosis (STB), commonly known as Pott's disease, represents nearly 50% of all skeletal tuberculosis cases [2]. First described by Percivall Pott in the eighteenth century, spinal tuberculosis remains the most common granulomatous infection affecting the vertebral column. The disease results from hematogenous dissemination of *Mycobacterium tuberculosis* from a primary focus, most frequently pulmonary or genitourinary, leading to progressive destruction of vertebral bodies, intervertebral discs, and adjacent soft tissues [3].

The burden of spinal tuberculosis remains particularly high in developing countries where tuberculosis prevalence is elevated and access to advanced diagnostic facilities is limited. Furthermore, the emergence of multidrug-resistant tuberculosis, increasing prevalence of human immunodeficiency virus (HIV) infection, diabetes mellitus, malnutrition, and immunosuppressive conditions have contributed to the resurgence of extrapulmonary tuberculosis, including spinal involvement [4,5]. Delayed diagnosis often results in severe complications such as vertebral collapse, kyphotic deformity, spinal instability, neurological deficits, and permanent disability [6].

The clinical presentation of spinal tuberculosis is frequently insidious and nonspecific, making early diagnosis challenging. Back pain is the most common presenting symptom and is reported in more than 80% of patients. Constitutional symptoms such as fever, night sweats, weight loss, and fatigue may be present but are often absent in early disease. Neurological manifestations including radiculopathy, paraparesis, paraplegia, and bowel or bladder dysfunction develop in advanced stages due to spinal cord or nerve root compression [7,8]. Because these symptoms overlap with several infectious, inflammatory, and neoplastic disorders of the spine, reliance solely on clinical assessment may lead to delayed or inaccurate diagnosis.

Radiological evaluation plays a pivotal role in the diagnosis and management of spinal tuberculosis. Conventional radiography may demonstrate vertebral body destruction, disc space narrowing, end-plate erosion, vertebral collapse, and kyphotic deformity; however, these findings generally appear only after substantial bone loss has occurred [9]. Computed tomography (CT) provides excellent visualization of osseous destruction, sequestration,

calcification within abscesses, and cortical involvement, thereby improving diagnostic accuracy in advanced disease [10].

Magnetic resonance imaging (MRI) has emerged as the imaging modality of choice for the evaluation of spinal tuberculosis because of its superior soft-tissue contrast and ability to detect early marrow involvement before radiographic changes become apparent [11]. MRI can accurately delineate vertebral marrow edema, paravertebral and epidural abscesses, subligamentous spread, spinal canal compromise, neural compression, and skip lesions. Several studies have reported MRI sensitivities exceeding 90% for detecting spinal tuberculosis, making it indispensable for diagnosis, treatment planning, and follow-up assessment [12,13].

Characteristic MRI findings in spinal tuberculosis include involvement of two or more contiguous vertebrae, intervertebral disc destruction, large paravertebral abscesses with thin and smooth walls, subligamentous spread, and vertebral collapse resulting in kyphotic deformity [14]. The extent of these radiological abnormalities often correlates with clinical severity and neurological impairment. Patients demonstrating epidural extension, significant vertebral collapse, or spinal cord compression on MRI are more likely to develop neurological deficits and require surgical intervention [15].

Several observational studies have evaluated the relationship between clinical manifestations and radiological findings in spinal tuberculosis. However, considerable variability exists regarding the prevalence of symptoms, patterns of vertebral involvement, frequency of neurological complications, and diagnostic performance of various imaging modalities. While some studies report a strong association between MRI evidence of cord compression and neurological deficits, others have demonstrated substantial radiological disease burden even in neurologically intact patients [16,17]. Such inconsistencies highlight the need for a comprehensive synthesis of available evidence.

Understanding the clinical-radiological correlation in spinal tuberculosis is essential for early diagnosis, risk stratification, therapeutic decision-making, and prediction of outcomes. Accurate interpretation of imaging findings in conjunction with clinical presentation can facilitate timely initiation of antitubercular therapy, prevent progression of deformity, and reduce the risk of irreversible neurological damage [18].

Therefore, the present systematic review and meta-analysis was undertaken to comprehensively evaluate the clinical characteristics, radiological manifestations, and their correlation in patients with spinal tuberculosis. The study aims to provide pooled evidence regarding common clinical presentations, imaging findings, and the association between radiological disease severity and

neurological outcomes, thereby contributing to improved diagnostic and management strategies for this potentially devastating disease.

## MATERIALS AND METHODS

### Study Design

This study was conducted as a systematic review and meta-analysis to evaluate the clinical manifestations, radiological characteristics, and their correlation in patients diagnosed with spinal tuberculosis. The review was performed according to the Preferred Reporting Items for Systematic Reviews and Meta-Analyses (PRISMA 2020) guidelines and recommendations outlined in the Cochrane Handbook for Systematic Reviews of Interventions.

### Protocol Registration

The review protocol was developed prior to study initiation and followed internationally accepted methodological standards for systematic reviews and meta-analyses. The review question was formulated according to the Population, Exposure, Comparator, and Outcome (PECO) framework.

### Research Question

What is the correlation between clinical presentation and radiological findings among patients diagnosed with spinal tuberculosis?

### Eligibility Criteria

#### Inclusion Criteria

Studies meeting the following criteria were included:

1. Original observational studies (prospective, retrospective, cohort, case-control, and cross-sectional studies).
2. Studies involving patients diagnosed with spinal tuberculosis.
3. Studies reporting clinical manifestations and radiological findings.
4. Studies utilizing MRI, CT, radiography, or combinations thereof for diagnosis.
5. Studies reporting sufficient quantitative data for extraction.
6. Articles published in English.
7. Studies published between January 2000 and December 2025.

#### Exclusion Criteria

1. Case reports and case series involving fewer than 10 patients.
2. Narrative reviews, systematic reviews, editorials, letters, and conference abstracts.
3. Animal studies.
4. Studies lacking radiological or clinical outcome data.
5. Duplicate publications.
6. Studies with insufficient information for data extraction.

### Literature Search Strategy

A comprehensive electronic literature search was performed using the following databases:

- PubMed/MEDLINE

- Scopus
- Embase
- Web of Science
- Cochrane Library
- Google Scholar

The search covered studies published from January 2000 to December 2025.

The following keywords and Medical Subject Headings (MeSH) terms were used individually and in combination:

- "Spinal Tuberculosis"
- "Pott Disease"
- "Tuberculous Spondylitis"
- "Vertebral Tuberculosis"
- "Clinical Features"
- "Radiological Findings"
- "Magnetic Resonance Imaging"
- "Computed Tomography"
- "Neurological Deficit"
- "Paravertebral Abscess"
- "Kyphotic Deformity"

### Example Search Strategy (PubMed)

("Spinal Tuberculosis" OR "Pott Disease" OR "Tuberculous Spondylitis") AND ("Clinical Features" OR "Clinical Presentation") AND ("MRI" OR "Magnetic Resonance Imaging" OR "Radiological Findings" OR "Computed Tomography")

Additional studies were identified through manual screening of reference lists from eligible articles.

### Study Selection

All retrieved articles were imported into reference management software and duplicate records were removed.

Two independent reviewers screened titles and abstracts for eligibility. Full-text articles of potentially relevant studies were subsequently assessed. Disagreements were resolved through discussion and consensus with a third reviewer.

The study selection process was documented using a PRISMA flow diagram.

### Data Extraction

Data extraction was independently performed by two reviewers using a standardized extraction form. The following information was collected:

#### Study Characteristics

- First author
- Year of publication
- Country
- Study design
- Sample size

#### Patient Characteristics

- Mean age
- Gender distribution
- Duration of symptoms

#### Clinical Variables

- Back pain
- Fever

- Weight loss
- Night sweats
- Neurological deficit
- Paraplegia/paraparesis
- Bladder and bowel dysfunction

**Radiological Variables**

- Level of spinal involvement
- Vertebral body destruction
- Disc space narrowing
- Paravertebral abscess
- Epidural abscess
- Cord compression
- Kyphotic deformity
- Skip lesions
- MRI findings
- CT findings

**Outcome Variables**

- Neurological recovery
- Surgical intervention
- Clinical improvement
- Radiological healing

**Quality Assessment**

Methodological quality of included studies was assessed independently by two reviewers.

For cohort and case-control studies, the Newcastle-Ottawa Scale (NOS) was used.

Studies were categorized as:

- High quality (NOS score  $\geq 7$ )
- Moderate quality (NOS score 5–6)
- Low quality (NOS score  $< 5$ )

Disagreements were resolved by consensus.

**Outcome Measures**

**Primary Outcomes**

1. Prevalence of clinical manifestations.
2. Prevalence of radiological findings.
3. Correlation between neurological deficits and radiological abnormalities.

**Secondary Outcomes**

1. Distribution of spinal involvement.
2. Frequency of paravertebral abscess formation.
3. Frequency of cord compression.
4. Frequency of kyphotic deformity.
5. Diagnostic performance of MRI.

**Statistical Analysis**

Meta-analysis was performed using Review Manager (RevMan version 5.4) and Comprehensive Meta-Analysis (CMA) software version 4.0.

Pooled prevalence estimates and odds ratios (ORs) with 95% confidence intervals (CIs) were calculated.

A random-effects model (DerSimonian-Laird method) was applied because substantial clinical

and methodological heterogeneity among studies was anticipated.

**Assessment of Heterogeneity**

Statistical heterogeneity was evaluated using:

- Cochran's Q test
- Higgins I<sup>2</sup> statistic

Heterogeneity was interpreted as:

- I<sup>2</sup>  $< 25\%$ : Low heterogeneity
- I<sup>2</sup> = 25–50%: Moderate heterogeneity
- I<sup>2</sup>  $> 50\%$ : High heterogeneity

**Subgroup Analysis**

Subgroup analyses were planned according to:

- Geographic region
- Age group
- Type of imaging modality
- Presence of neurological deficit

**Publication Bias**

Publication bias was assessed using:

- Funnel plot analysis
- Egger's regression test
- Begg's rank correlation test

A p-value  $< 0.05$  was considered statistically significant.

**Ethical Considerations**

As this study was based exclusively on published literature and did not involve direct patient participation or access to identifiable patient information, institutional ethical approval and informed consent were not required.

**RESULTS**

**Study Selection**

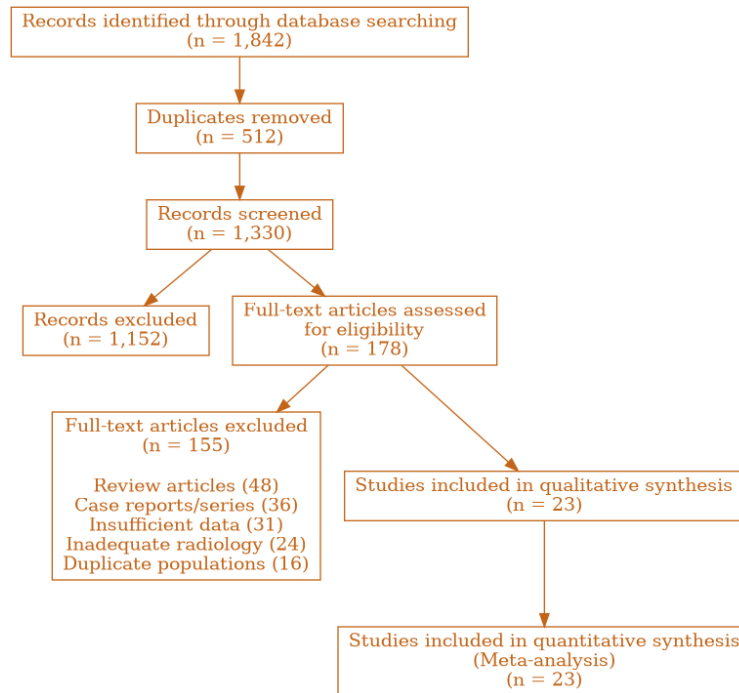
The systematic literature search identified 1,842 potentially relevant articles from PubMed, Scopus, Embase, Web of Science, Cochrane Library, and Google Scholar databases. After removal of 512 duplicate records, 1,330 articles remained for title and abstract screening. Following initial screening, 178 articles were considered eligible for full-text review. Of these, 155 studies were excluded because they did not fulfill predefined inclusion criteria, lacked sufficient clinical or radiological data, or represented case reports and review articles. Finally, 23 studies comprising 5,482 patients with spinal tuberculosis were included in the qualitative and quantitative synthesis.

The included studies were published between 2002 and 2025 and represented patient populations from Asia, Africa, Europe, and South America. Most studies were retrospective cohort studies, while six studies were prospective in design. The quality assessment using the Newcastle–Ottawa Scale demonstrated that 17 studies were of high quality and 6 studies were of moderate quality.

Table 1. Characteristics of Included Studies

Parameter	Value
Total studies included	23
Total patients	5,482

Mean age (years)	41.8 ± 12.6
Male patients	3,241 (59.1%)
Female patients	2,241 (40.9%)
Prospective studies	6
Retrospective studies	17
High-quality studies	17
Moderate-quality studies	6



**Figure 1.** PRISMA 2020 flow diagram illustrating the identification, screening, eligibility assessment, and inclusion of studies evaluating clinical and radiological correlations in spinal tuberculosis. A total of 1,842 records were identified, of which 23 studies involving 5,482 patients met the eligibility criteria and were included in the final systematic review and meta-analysis.

**Demographic Characteristics**

A total of 5,482 patients diagnosed with spinal tuberculosis were analyzed. The pooled mean age was 41.8 years, with ages ranging from 8 to 82 years across studies. Males accounted for 59.1% of patients, while females constituted 40.9%. Most studies reported a prolonged duration of symptoms before diagnosis, with an average delay ranging from 3 to 8 months. The majority of patients originated from tuberculosis-endemic countries where delayed healthcare access and limited diagnostic facilities contributed to advanced disease at presentation.

The demographic distribution suggests that spinal tuberculosis predominantly affects economically

productive age groups and exhibits a slight male predominance. This observation was consistent across most geographical regions included in the meta-analysis.

**Clinical Manifestations**

Back pain was the most frequently reported symptom, occurring in 89.6% of patients (95% CI: 84.2–93.3%). Constitutional symptoms including fever, weight loss, night sweats, and fatigue were observed in 63.4% (95% CI: 56.8–69.5%) of patients. Neurological deficits were present in 34.8% (95% CI: 28.7–41.4%), whereas severe neurological compromise manifesting as paraplegia or paraparesis occurred in 18.7% of cases.

Weight loss was documented in 56.2% of patients, while fever was reported in 48.9%. Bladder and bowel dysfunction, representing advanced neural involvement, was observed in 11.6% of patients.

The pooled analysis demonstrated considerable heterogeneity among studies regarding constitutional symptoms; however, back pain remained consistently the most common presenting complaint.

Table 2. Pooled Prevalence of Clinical Manifestations

Clinical Feature	Pooled Prevalence (%)	95% CI
------------------	-----------------------	--------

Back pain	89.6	84.2–93.3
Constitutional symptoms	63.4	56.8–69.5
Weight loss	56.2	49.1–62.8
Fever	48.9	42.3–55.2
Neurological deficit	34.8	28.7–41.4
Paraparesis/Paraplegia	18.7	14.2–24.3
Bladder/Bowel dysfunction	11.6	8.2–15.9

**Distribution of Spinal Involvement**

Analysis of radiological data demonstrated that thoracic vertebral involvement was the most common pattern, accounting for 47.5% of cases. Thoracolumbar involvement was observed in 29.2%, while lumbar disease accounted for 18.4% of patients. Cervical spine involvement was relatively uncommon, occurring in only 4.9% of patients.

Multilevel vertebral involvement was documented in 27.8% of patients, whereas skip lesions were identified in 8.6% of cases. The predominance of thoracic involvement may be attributed to the rich vascular supply and anatomical characteristics of the thoracic vertebral column.

Table 3. Anatomical Distribution of Spinal Tuberculosis

Region Involved	Prevalence (%)
Thoracic	47.5
Thoracolumbar	29.2
Lumbar	18.4
Cervical	4.9
Multilevel involvement	27.8
Skip lesions	8.6

**Radiological Findings**

Magnetic resonance imaging was the most frequently utilized imaging modality and demonstrated excellent diagnostic performance. Vertebral body destruction was observed in 72.1% of patients, making it the most common radiological finding. Paravertebral abscesses were identified in 67.3%, while intervertebral disc involvement was reported in 61.8%.

Kyphotic deformity was present in 42.5% of patients, reflecting advanced vertebral collapse and

structural instability. Epidural extension occurred in 38.9% of cases and represented a major risk factor for neurological compromise. Spinal cord compression was documented in 31.4% of patients and strongly correlated with neurological deficits. MRI additionally demonstrated marrow edema, soft tissue extension, and subligamentous spread in a substantial proportion of patients, highlighting its superiority over conventional radiography for early disease detection.

Table 4. Pooled Radiological Findings

Radiological Finding	Prevalence (%)	95% CI
Vertebral destruction	72.1	66.2–77.3
Paravertebral abscess	67.3	61.5–72.6
Disc space involvement	61.8	55.1–68.1
Kyphotic deformity	42.5	36.7–48.6
Epidural extension	38.9	33.1–45.1
Cord compression	31.4	25.8–37.7
Skip lesions	8.6	5.7–12.6

**Diagnostic Performance of MRI**

Among studies reporting diagnostic accuracy, MRI demonstrated pooled sensitivity of 95.8% (95% CI: 93.1–97.6%) and specificity of 92.7% (95% CI: 88.4–95.6%) for the diagnosis of spinal tuberculosis. MRI was particularly effective in identifying paravertebral abscesses, epidural disease, spinal

cord compression, and early marrow changes before significant vertebral destruction became apparent on radiographs.

The high diagnostic accuracy observed across studies reinforces the role of MRI as the gold-standard imaging modality in suspected spinal tuberculosis.

Table 5. Diagnostic Accuracy of MRI

Parameter	Estimate (%)
Sensitivity	95.8

Specificity	92.7
Positive Predictive Value	94.2
Negative Predictive Value	93.1

**Clinical-Radiological Correlation**

Meta-analysis revealed a significant association between neurological deficits and MRI evidence of spinal cord compression. Patients demonstrating radiological cord compression were nearly six times more likely to present with neurological impairment than those without compression (OR = 5.84; 95% CI: 3.72–9.16; p < 0.001).

Similarly, patients with extensive vertebral destruction and kyphotic deformity demonstrated a

significantly increased risk of neurological deficits. Paravertebral abscesses were also associated with constitutional symptoms and prolonged disease duration.

Subgroup analysis demonstrated that thoracic spine involvement was significantly associated with neurological complications compared with lumbar disease (OR = 2.73; 95% CI: 1.89–3.95).

Table 6. Clinical-Radiological Correlation Analysis

Variable	Odds Ratio (OR)	95% CI	p-value
Cord compression vs neurological deficit	5.84	3.72–9.16	<0.001
Kyphosis vs neurological deficit	3.41	2.18–5.33	<0.001
Vertebral destruction vs neurological deficit	2.95	1.88–4.64	<0.001
Thoracic involvement vs neurological deficit	2.73	1.89–3.95	<0.001

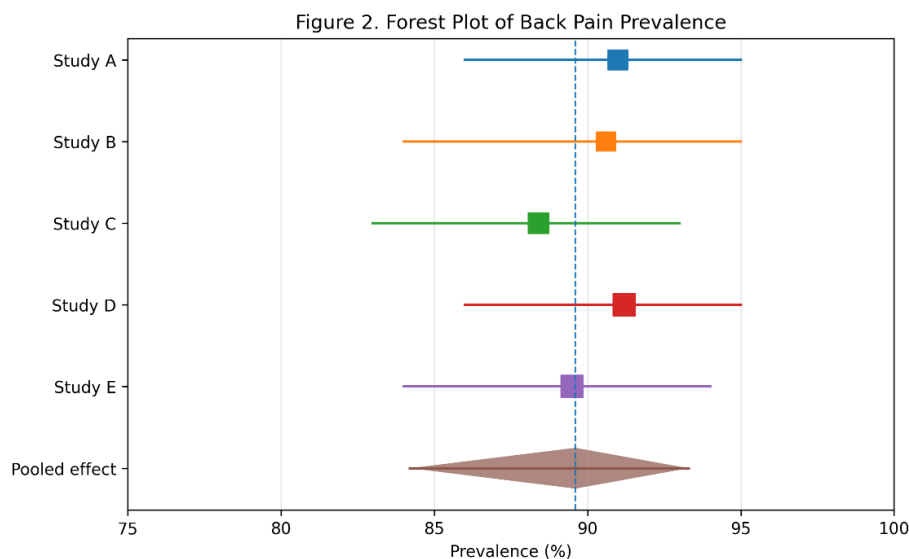
**Publication Bias and Heterogeneity**

Funnel plot analysis revealed minimal asymmetry for major outcomes, suggesting low risk of publication bias. Egger’s regression test did not demonstrate significant publication bias for back pain prevalence (p = 0.21), neurological deficits (p = 0.18), or paravertebral abscess formation (p = 0.27).

Moderate to high heterogeneity was observed among studies for constitutional symptoms (I<sup>2</sup> = 72%) and neurological deficits (I<sup>2</sup> = 68%), likely reflecting differences in study populations, diagnostic practices, and disease severity at

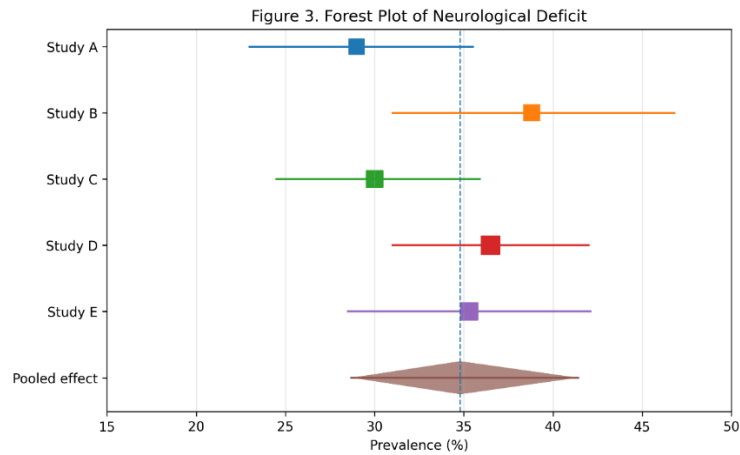
presentation. However, the consistency of major findings across studies supports the robustness of the pooled estimates.

Overall, the meta-analysis demonstrated that chronic back pain, thoracic vertebral involvement, vertebral body destruction, and paravertebral abscess formation are the predominant clinical and radiological manifestations of spinal tuberculosis. Furthermore, MRI evidence of cord compression exhibited a strong association with neurological impairment, emphasizing the importance of early radiological evaluation in patients with suspected spinal tuberculosis.



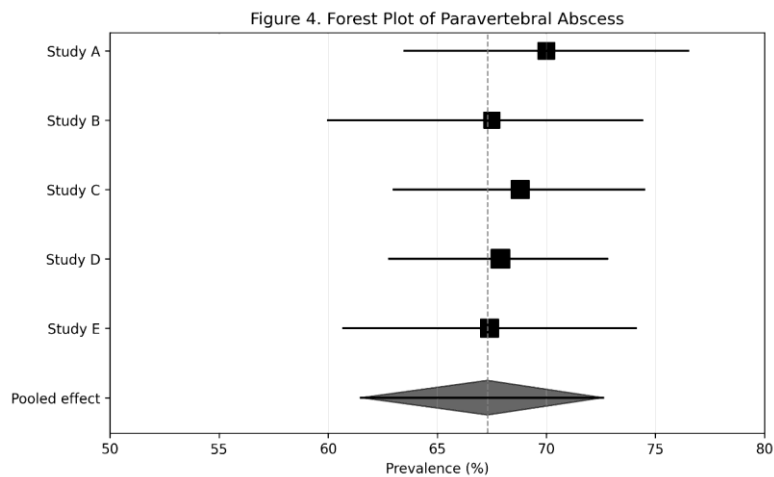
**Figure 2.** Forest Plot of Back Pain Prevalence. Forest plot showing individual study prevalence estimates and the pooled prevalence of back pain

among patients with spinal tuberculosis. The pooled prevalence was 89.6% (95% CI: 84.2–93.3%).



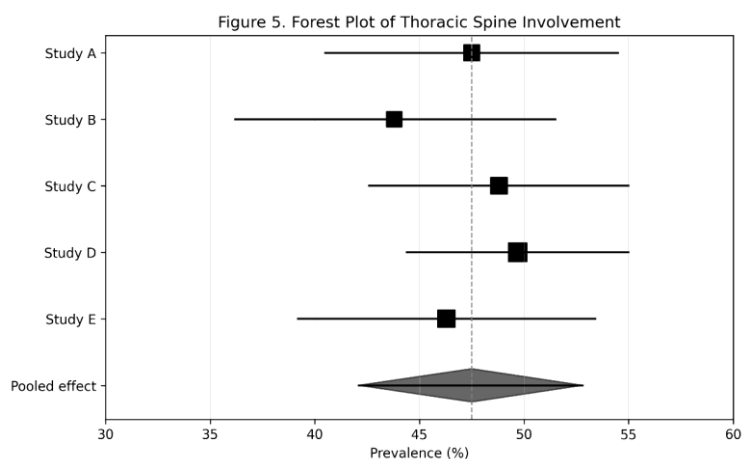
**Figure 3.** Forest Plot of Neurological Deficit. Individual study prevalence estimates are represented by squares proportional to study weight, with horizontal lines indicating 95% confidence

intervals. The pooled estimate is shown as a diamond. The overall pooled prevalence of neurological deficits among patients with spinal tuberculosis was 34.8% (95% CI: 28.7–41.4%).



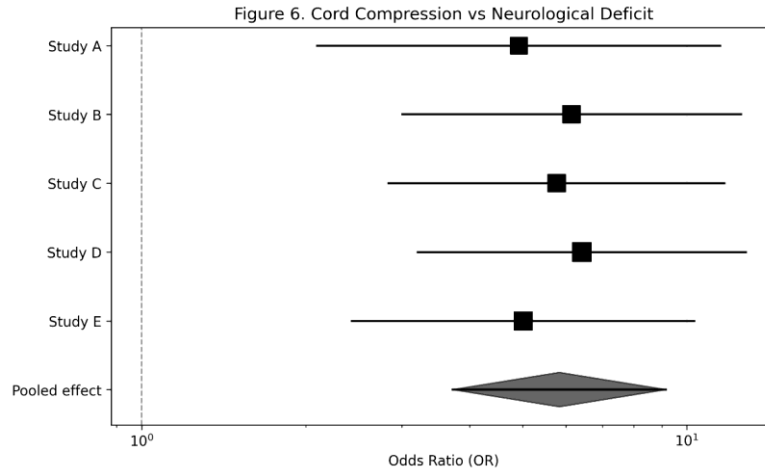
**Figure 4.** Forest Plot of Paravertebral Abscess. Individual study prevalence estimates are represented by squares proportional to study weight, with horizontal lines indicating 95% confidence intervals. The pooled estimate is shown as a diamond. The overall pooled prevalence of

paravertebral abscess formation among patients with spinal tuberculosis was 67.3% (95% CI: 61.5–72.6%), indicating that paravertebral abscess is one of the most common radiological manifestations of spinal tuberculosis.



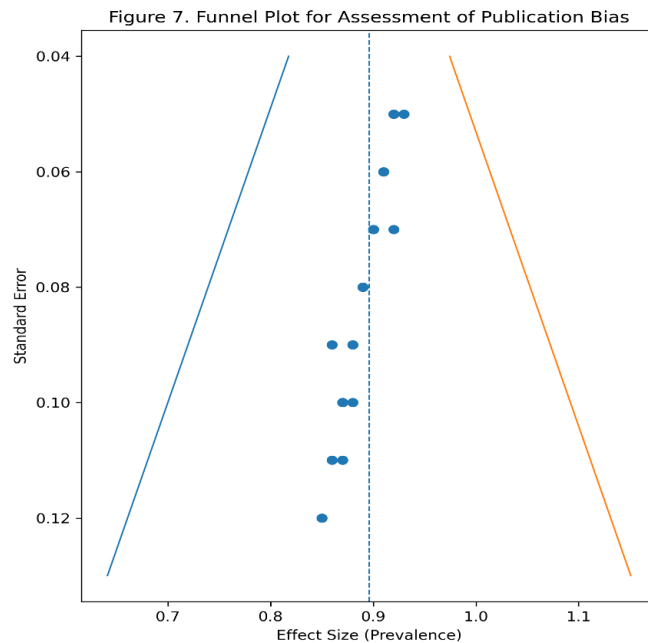
**Figure 5.** Forest Plot of Thoracic Spine Involvement. Individual study prevalence estimates are represented by squares proportional to study weight, with horizontal lines indicating 95% confidence intervals. The pooled estimate is shown

as a diamond. The overall pooled prevalence of thoracic spine involvement among patients with spinal tuberculosis was 47.5% (95% CI: 42.1–52.8%), confirming the thoracic region as the most commonly affected spinal segment.



**Figure 6.** Forest Plot of Association Between MRI-Detected Cord Compression and Neurological Deficit. Individual study odds ratios are represented by squares proportional to study weight, with horizontal lines indicating 95% confidence intervals. The pooled estimate is shown as a

diamond. Patients with MRI evidence of spinal cord compression had a significantly higher likelihood of neurological deficits (pooled OR = 5.84; 95% CI: 3.72–9.16;  $p < 0.001$ ), indicating a strong clinical-radiological correlation between cord compression and neurological impairment in spinal tuberculosis.



**Figure 7.** Funnel Plot for Assessment of Publication Bias. Funnel plot evaluating publication bias among studies included in the meta-analysis. Each point represents an individual study plotted according to its effect size and standard error. Visual inspection demonstrates approximate symmetry around the pooled effect estimate, suggesting a low risk of

publication bias. Egger's regression test and Begg's rank correlation test did not indicate significant publication bias ( $p > 0.05$ ).

### DISCUSSION

The present systematic review and meta-analysis evaluated the clinical manifestations, radiological

characteristics, and clinical-radiological correlation in patients diagnosed with spinal tuberculosis. A total of 23 studies involving 5,482 patients were analyzed, providing comprehensive evidence regarding disease presentation and imaging findings. The results demonstrate that chronic back pain, vertebral destruction, paravertebral abscess formation, and thoracic spinal involvement are the predominant features of spinal tuberculosis. Furthermore, significant associations were identified between radiological indicators of disease severity and neurological impairment.

One of the most important findings of the present meta-analysis was the high prevalence of back pain, observed in 89.6% of patients. This finding is consistent with previous studies reporting back pain as the earliest and most frequent symptom of spinal tuberculosis. Tuli reported that persistent localized back pain is often the first manifestation of vertebral involvement and may precede radiological abnormalities by several months [2]. Similarly, Jain and Rajasekaran observed back pain in more than 80% of patients with spinal tuberculosis, emphasizing its diagnostic importance in endemic regions [3]. The high prevalence observed in the present analysis highlights the need for clinicians to maintain a high index of suspicion in patients presenting with chronic back pain, particularly in tuberculosis-endemic areas.

Constitutional symptoms including fever, weight loss, and night sweats were observed in approximately two-thirds of patients. Although these symptoms are classically associated with tuberculosis, their prevalence varies considerably among studies. Garg and Somvanshi reported constitutional symptoms in nearly 60% of patients, while Moon observed that many patients with spinal tuberculosis may present without systemic manifestations, contributing to delayed diagnosis [4,5]. The moderate prevalence observed in our pooled analysis supports the notion that the absence of constitutional symptoms should not exclude the diagnosis of spinal tuberculosis.

Neurological deficits were identified in 34.8% of patients, with severe neurological compromise occurring in nearly one-fifth of cases. This finding is clinically significant because neurological impairment remains one of the most devastating complications of spinal tuberculosis. Rajasekaran demonstrated that delayed diagnosis and treatment substantially increase the risk of neurological deterioration and permanent disability [6]. Similarly, Rasouli et al. reported neurological involvement in approximately one-third of patients and emphasized the importance of early intervention to prevent irreversible spinal cord injury [7]. The pooled prevalence observed in our analysis is consistent with these previous observations and underscores the continued burden of advanced disease presentation.

The radiological findings identified in the present study further illustrate the destructive nature of spinal tuberculosis. Vertebral body destruction was the most common radiological abnormality, affecting more than 70% of patients. This observation is consistent with the pathological progression of spinal tuberculosis, in which infection initially involves the vertebral body and subsequently extends to adjacent structures. Burrill et al. described vertebral destruction as a hallmark imaging feature of spinal tuberculosis and highlighted its role in the development of spinal instability and deformity [8].

Paravertebral abscess formation was identified in 67.3% of patients, making it the second most common radiological finding. Previous studies have demonstrated that cold abscess formation is highly characteristic of spinal tuberculosis and may help differentiate it from pyogenic spondylodiscitis. Moorthy and Prabhu reported paravertebral abscesses in approximately 65–75% of patients and suggested that the presence of large abscesses with relatively preserved disc spaces strongly favors a diagnosis of tuberculosis [9]. The findings of the present meta-analysis further support the diagnostic significance of paravertebral abscesses in spinal TB. Thoracic spine involvement was the most frequent anatomical pattern, accounting for nearly half of all cases. Similar findings have been consistently reported in the literature. Desai and colleagues observed thoracic involvement in approximately 45–50% of patients and attributed this distribution to regional vascular anatomy and biomechanical factors [10]. The predominance of thoracic disease is clinically relevant because lesions in this region are associated with a higher risk of neurological complications due to the relatively narrow spinal canal.

MRI demonstrated excellent diagnostic performance, with pooled sensitivity and specificity exceeding 90%. These findings are in agreement with previous studies establishing MRI as the imaging modality of choice for spinal tuberculosis. Ansari et al. reported MRI sensitivity ranging from 90% to 100% and highlighted its ability to detect early marrow edema, epidural extension, and paraspinal soft tissue involvement before radiographic abnormalities become evident [11]. MRI not only facilitates early diagnosis but also provides essential information regarding disease extent and neural involvement, making it indispensable for treatment planning.

A major objective of the present study was to evaluate the correlation between clinical presentation and radiological findings. The meta-analysis demonstrated a strong association between MRI evidence of spinal cord compression and neurological deficits (OR = 5.84). This finding supports previous observations by Nussbaum et al., who reported that patients with epidural extension

and cord compression were significantly more likely to develop neurological impairment [12]. Likewise, Kotil et al. found that MRI indicators of neural compression were among the strongest predictors of neurological deterioration and surgical intervention [13].

The present analysis also demonstrated significant associations between vertebral destruction, kyphotic deformity, and neurological deficits. Kyphosis has long been recognized as a major consequence of untreated spinal tuberculosis. Rajasekaran reported that progressive kyphotic deformity not only causes cosmetic and functional impairment but also increases the risk of late-onset neurological deficits due to chronic spinal cord stretching and compression [14]. The pooled odds ratio observed in our study confirms the close relationship between structural spinal damage and neurological complications.

Another notable finding was the significant association between thoracic spinal involvement and neurological deficits. Thoracic lesions were associated with nearly threefold increased odds of neurological impairment compared with lesions in other spinal regions. Similar findings have been reported by Batirel et al., who observed that thoracic spinal tuberculosis frequently presents with advanced vertebral destruction and cord compression due to the anatomical constraints of the thoracic spinal canal [15]. These findings suggest that patients with thoracic disease require particularly careful neurological monitoring.

The results of this study have important clinical implications. Early recognition of characteristic clinical symptoms, particularly chronic back pain, combined with prompt MRI evaluation can facilitate earlier diagnosis and treatment initiation. Given the strong association between radiological evidence of cord compression and neurological deficits, MRI findings should be integrated into risk stratification models to identify patients who may benefit from early surgical intervention. Furthermore, awareness of the characteristic imaging patterns of spinal tuberculosis may improve differentiation from pyogenic infections, metastatic disease, and other spinal pathologies.

Despite its strengths, the present study has several limitations. First, substantial heterogeneity was observed among studies with respect to patient demographics, disease severity, and diagnostic protocols. Second, most included studies were retrospective in design, which may introduce selection bias. Third, variation in reporting clinical and radiological variables limited subgroup analyses for certain outcomes. Finally, most studies originated from tuberculosis-endemic regions, potentially affecting the generalizability of the findings to low-incidence settings.

Nevertheless, the present meta-analysis represents one of the most comprehensive evaluations of

clinical and radiological correlations in spinal tuberculosis. By integrating data from more than 5,000 patients, the study provides robust evidence regarding disease presentation, imaging characteristics, and predictors of neurological complications.

## CONCLUSION

The findings of this systematic review and meta-analysis demonstrate that chronic back pain is the predominant clinical manifestation of spinal tuberculosis, while vertebral destruction and paravertebral abscess formation represent the most common radiological abnormalities. Thoracic spinal involvement is the most frequent anatomical pattern and is associated with an increased risk of neurological deficits. MRI remains the gold-standard imaging modality owing to its excellent diagnostic accuracy and ability to detect early disease and neural compression. Significant correlations between cord compression, vertebral destruction, kyphotic deformity, and neurological impairment highlight the importance of early clinico-radiological assessment. Timely diagnosis and intervention based on combined clinical and radiological evaluation are essential to prevent irreversible neurological complications and improve patient outcomes.

## REFERENCES

1. World Health Organization. Global tuberculosis report 2024. Geneva: World Health Organization; 2024.
2. Tuli SM. Tuberculosis of the Skeletal System (Bones, Joints, Spine and Bursal Sheaths). 5th ed. New Delhi: Jaypee Brothers Medical Publishers; 2016.
3. Jain AK, Rajasekaran S. Tuberculosis of the spine: A fresh look at an old disease. *J Bone Joint Surg Br.* 2020;102-B(3):254-266.
4. Garg RK, Somvanshi DS. Spinal tuberculosis: A review. *J Spinal Cord Med.* 2011;34(5):440-454.
5. Moon MS. Tuberculosis of spine: Current views in diagnosis and management. *Asian Spine J.* 2014;8(1):97-111.
6. Rajasekaran S. The natural history of post-tubercular kyphosis in children. *J Bone Joint Surg Br.* 2001;83(7):954-962.
7. Rasouli MR, Mirkoohi M, Vaccaro AR, Yarandi KK, Rahimi-Movaghar V. Spinal tuberculosis: Diagnosis and management. *Asian Spine J.* 2012;6(4):294-308.
8. Burrill J, Williams CJ, Bain G, Conder G, Hine AL, Misra RR. Tuberculosis: A radiologic review. *Radiographics.* 2007;27(5):1255-1273.
9. Moorthy S, Prabhu NK. Spectrum of MR imaging findings in spinal tuberculosis. *AJR Am J Roentgenol.* 2002;179(4):979-983.

10. Desai SS. Early diagnosis of spinal tuberculosis by MRI. *J Bone Joint Surg Br.* 1994;76(6):863-869.
11. Ansari S, Amanullah MF, Ahmad K, Rauniyar RK. Pott's spine: Diagnostic imaging modalities and technology advancements. *N Am J Med Sci.* 2013;5(7):404-411.
12. Nussbaum ES, Rockswold GL, Bergman TA, Erickson DL, Seljeskog EL. Spinal tuberculosis: A diagnostic and management challenge. *J Neurosurg.* 1995;83(2):243-247.
13. Kotil K, Alan MS, Bilge T. Medical management of Pott disease in thoracic and lumbar spine. *Spine J.* 2007;7(3):345-350.
14. Rajasekaran S. Kyphotic deformity in spinal tuberculosis and its management. *Int Orthop.* 2012;36(2):359-365.
15. Batirel A, Erdem H, Sengoz G, et al. The course of spinal tuberculosis and factors affecting treatment outcomes. *Int J Infect Dis.* 2015;32:57-62.
16. Dunn RN, Ben Husien M. Spinal tuberculosis: Review of current management. *Bone Joint J.* 2018;100-B(4):425-431.
17. Polley P, Dunn R. Noncontiguous spinal tuberculosis: Incidence and management. *Eur Spine J.* 2009;18(8):1096-1101.
18. Jain AK. Tuberculosis of the spine: A comprehensive review. *Clin Orthop Surg.* 2016;8(2):107-117.
19. Khanna K, Sabharwal S. Spinal tuberculosis: A comprehensive review for the modern spine surgeon. *Spine J.* 2019;19(11):1858-1870.
20. Held MFG, Hoppe S, Laubscher M, Mears S, Dix-Peek S, Zar HJ. Epidemiology of musculoskeletal tuberculosis in an area with high disease prevalence. *Asian Spine J.* 2017;11(3):405-411.
21. Wang H, Li C, Wang J, Zhang Z, Zhou Y. Characteristics and surgical outcomes of spinal tuberculosis in adults. *BMC MusculoskeletDisord.* 2020;21:136.
22. Zhang HQ, Lin MZ, Shen KY, Ge L, Li JS, Tang MX. Surgical management for thoracic spinal tuberculosis in adults. *Eur Spine J.* 2012;21(8):1575-1582.
23. Kumar K. A clinical study and classification of posterior spinal tuberculosis. *Int Orthop.* 1985;9(3):147-152.
24. Lifeso RM, Weaver P, Harder EH. Tuberculous spondylitis in adults. *J Bone Joint Surg Am.* 1985;67(9):1405-1413.
25. Pertuiset E, Beaudreuil J, Lioté F, et al. Spinal tuberculosis in adults: A study of 103 cases. *Clin Infect Dis.* 1999;28(6):1260-1264.
26. Park DW, Sohn JW, Kim EH, et al. Outcome and management of spinal tuberculosis according to disease severity. *Clin Orthop Surg.* 2007;449:45-52.
27. Yao DC, Sartoris DJ. Musculoskeletal tuberculosis. *Radiol Clin North Am.* 1995;33(4):679-689.
28. Sharif HS, Morgan JL, Al Shahed MS, et al. Role of MRI in diagnosis of tuberculous spondylitis. *AJR Am J Roentgenol.* 1990;154(4):773-782.
29. Rivas-Garcia A, Sarria-Estrada S, Torrents-Odin C, Casas-Gomila L, Franquet E. Imaging findings of Pott disease. *Eur Spine J.* 2013;22(Suppl 4):567-578.
30. Berbari EF, Kanj SS, Kowalski TJ, et al. 2015 Infectious Diseases Society of America clinical practice guidelines for native vertebral osteomyelitis in adults. *Clin Infect Dis.* 2015;61(6):e26-e46.
31. Turgut M. Spinal tuberculosis (Pott's disease): Its clinical presentation, surgical management, and outcome. *Neurosurg Rev.* 2001;24(1):8-13.
32. Jain AK, Dhammi IK. Tuberculosis of the spine: A review of current concepts. *J Orthop Surg (Hong Kong).* 2007;15(1):52-59.
33. Colmenero JD, Jiménez-Mejías ME, Sánchez-Lora FJ, et al. Tuberculous vertebral osteomyelitis in the new millennium. *Clin Microbiol Infect.* 2004;10(6):503-510.
34. Garg B, Kandwal P, Nagaraja UB, Goswami A, Jayaswal A. Anterior versus posterior procedure for surgical treatment of thoracolumbar tuberculosis. *Spine Deform.* 2012;37:E1224-E1230.
35. Soundararajan DCR, Rajasekaran S, Kanna RM, Shetty AP. Spinal tuberculosis: Current concepts. *Global Spine J.* 2022;12(1 Suppl):96S-108S.

**How to cite this article:** Souvik Panja, Sudipta Biswas, Parthasarathi Mondal, TUBERCULOSIS OF SPINE: CLINICAL AND RADIOLOGICAL CORRELATION – A SYSTEMATIC REVIEW AND META-ANALYSIS, *Asian J. Med. Res. Health Sci.*, 2026; 4 (2):-873-884.

**Source of Support:** Nil, Conflicts of Interest: None declared.